

# Intra-abdominal hypertension complicating pancreatitis-induced acute respiratory distress syndrome in three patients on extracorporeal membrane oxygenation

Lee Feddy<sup>1</sup>, Julian Barker<sup>1</sup>, Pete Fawcett<sup>2</sup>, Ignacio Malagon<sup>1</sup>

<sup>1</sup>Consultant in Cardiothoracic Anaesthesia and Intensive Care, University Hospital of South Manchester, United Kingdom

<sup>2</sup>ECMO Coordinator, University Hospital of South Manchester, UK United Kingdom

## Abstract

**Background:** Severe acute pancreatitis is associated with severe multiorgan failure from 15 to 50%, depending on the series. In some of these patients, conventional methods of ventilation and respiratory support will fail, demanding the use of extracorporeal membrane oxygenation (ECMO). Abdominal compartment syndrome is potentially harmful in this cohort of patients. We describe the successful treatment of three patients with severe acute pancreatitis who underwent respiratory ECMO and where intra abdominal pressure was monitored regularly.

**Methods:** Retrospective review of case notes.

**Results:** Three patients with severe acute pancreatitis requiring ECMO suffered from increased intra abdominal pressure during their ICU stay. No surgical interventions were taken to relieve abdominal compartment syndrome. Survival to hospital discharge was 100%

**Conclusions:** Monitoring intraabdominal pressure is a valuable adjunct to decision making while caring for these high-risk critically ill patients.

**Key words:** severe acute pancreatitis, intraabdominal pressure, ECMO

Anesthesiology Intensive Therapy 2015 [ahead of print]

Acute pancreatitis (AP) is an inflammatory disorder induced mostly by gallstones or excessive alcohol consumption. Clinical presentation varies from mild abdominal symptoms to severe multi-organ failure. Approximately 20% of patients present with the most severe form, severe acute pancreatitis (SAP) [1]. It is widely accepted that mortality has decreased over the past decades. However, patients with SAP requiring admission to an intensive care unit (ICU) have mortality rates between 30–50%. There is no particular treatment that has demonstrated in a controlled randomised trial to have a significant impact on reduction of mortality in this cohort of patients [2, 3].

The incidence of pulmonary complications in SAP varies from 15% to 55%, and in its more severe form will induce fulminant acute respiratory distress syndrome (ARDS) [4]. The use of venous-venous extracorporeal membrane oxygenation (VV-ECMO), or respiratory ECMO, is becoming common

practice in patients with SAP and ARDS, where conventional mechanical ventilation has failed. Survival in this very specific cohort of patients varies from 63% to 100% [5, 6].

Intra-abdominal hypertension (IAH), defined as a sustained increase in intra-abdominal pressure (IAP) above 12 mm Hg, is prevalent in mechanically ventilated patients while abdominal compartment syndrome (ACS) occurs in less than 5% of mechanically ventilated patients [7].

Patients on VV-ECMO with SAP have many of the risk factors to potentially develop ACS [8]. We describe three male patients successfully treated with VV-ECMO for respiratory failure secondary to acute alcoholic pancreatitis, where IAP was measured actively during admission to an ICU.

## METHODS

Case notes of three patients with SAP that required VV-ECMO were retrospectively reviewed. Written informed

consent was obtained from all patients to use data from their case notes in an anonymised way for the purpose of scientific publication. Data collection included extricating data from written, as well as electronic files. Intra-abdominal pressure was measured using the standard technique previously described [8].

### PATIENT 1

A 42-year-old man with a history of hypertension and obesity, and with a body mass index (BMI) of 34 (weight 110 kg), presented with acute alcoholic pancreatitis. Serum amylase > 2000 U L<sup>-1</sup> and CT imaging of the pancreas revealed a large inflammatory mass and 50% necrosis. ARDS developed and he required intubation on day 5. On day 13 he was transferred to our unit for ECMO support (Table 1). A 31F Avalon cannula (Avalon Elite<sup>®</sup>, MAQUET Holding B.V. & Co. KG, Germany) was inserted into the right internal jugular vein (RIJ). Saturations remained low and an additional right femoral 22F venous drainage line was added and saturations improved to 85%. Further management consisted of cardiovascular support, nasogastric (NG) feeding and antimicrobial therapy. A surgical opinion was sought and conservative management felt to be most appropriate.

By day 4, oxygenation saturations remained in the mid 80s and a decision to change the oxygenator and add a second one improved saturations to 97%. Over the next 2 weeks the patient developed IAH progressing to ACS (IAP up to 37 mm Hg). Enteral feeding was switched to total parenteral nutrition. Renal failure ensued and he required renal replacement therapy with continuous veno-venous haemofiltration (CVVH). Inflammatory markers remained static and a repeat CT scan demonstrated 70% necrosis with fluid collection around the tail. However, no gas was identified. After careful consideration, conservative management was adopted.

Nevertheless, a laparostomy for management of ACS was considered. Over the period of admission in our intensive care unit a total of three ultrasound-guided ascitic drains were inserted by a radiologist. On day 17, gastrointestinal function did return and NG feeding was recommenced. On day 18, neutropenia developed with a white cell count of  $1 \times 10^9$  cells per litre (neutrophils 0.01). Granulocyte colony stimulating factor (G-CSF), methylprednisolone and IV immunoglobulins were commenced with an improvement in the white cell count. A bone marrow aspirate showed evidence of haemophagocytosis.

Multiple attempts to wean the patient off ECMO failed with worsening metabolic acidosis and poor oxygenation. A further CT scan revealed virtual total pancreatic necrosis. Although repeated drops in haemoglobin led to a CT angiogram being performed to rule out gastrointestinal bleeding, this was non-diagnostic. An oesophagogastrodu-

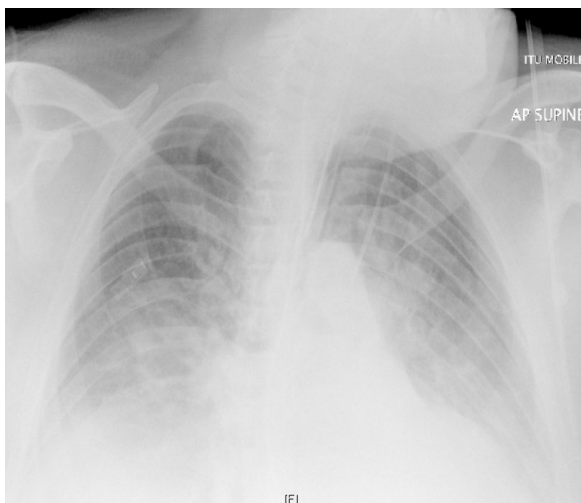
**Table 1.** Pre ECMO referral data

	Patient 1	Patient 2	Patient 3
Age	42	30	46
Number of days ventilated	13	< 1	10
PaO <sub>2</sub> /FiO <sub>2</sub>	67	42.75	58
PEEP	14	10	12
CXR quadrants infiltrated (pre ECMO)	3 (Fig. 1)	3 (Fig. 2)	4 (Fig. 3)
Murray Score	3.75	3.25	3.5
BMI	34	33	29.4
Pancreatic Necrosis demonstrated on computer tomography (CT)	50%	30%	Discernible
Heart rate	120 sinus	140 sinus	127 sinus
Vasopressors/ Inotropes	Noradrenaline	Noradrenaline	Nil
Positive Fluid balance since admission (L)	8	9	5
Urine output (mL h <sup>-1</sup> )	40 on frusemide 10 mg hr <sup>-1</sup>	10 on frusemide 20 mg h <sup>-1</sup>	100 on frusemide 10 mg h <sup>-1</sup>
Feed	Total Parenteral Nutrition (TPN)	NG	NG
Absorbing	No	Yes	Yes

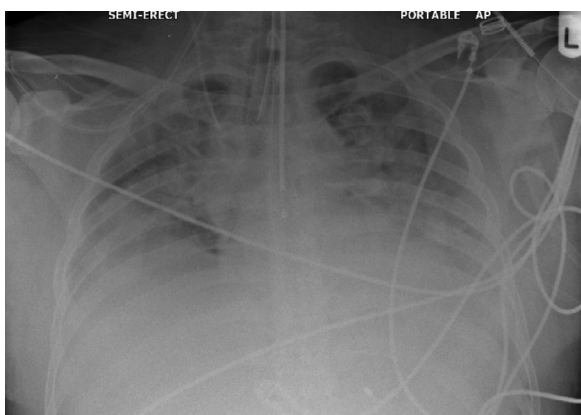
odenoscopy revealed the appearance of portal hypertensive gastropathy but no active bleeding. A tracheostomy was performed on day 25. ECMO was finally stopped successfully after a total of 637 hours.

### PATIENT 2

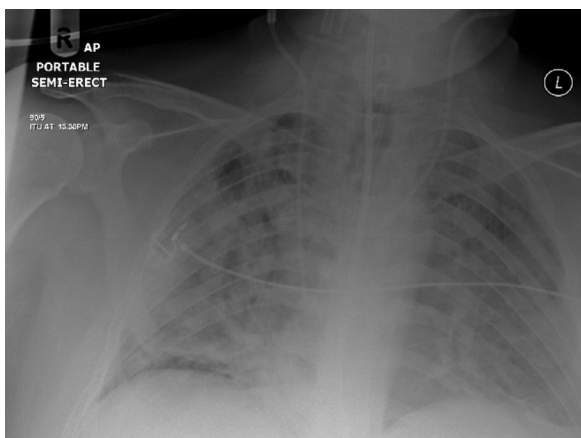
A 30-year-old male, weighing 95 kg, presented with typical features of severe alcoholic pancreatitis. CT imaging demonstrated 30% necrosis of the pancreatic tail. He was admitted to the general intensive care unit for monitoring and observation. 24 hours later he had a seizure thought to be caused by alcohol withdrawal. Sedation and intubation were performed. Conventional ventilation and a trial of Nitric Oxide were unable to maintain adequate oxygenation. Proning was deemed unsafe due to desaturations to 70% while lying flat. Blood gases prior to ECMO revealed a pH 7.0, pO<sub>2</sub> 5.7 kPa, pCO<sub>2</sub> 15.9 kPa, BE -4.7 and HCO<sub>3</sub> 20.6 mmol L<sup>-1</sup> (Table 1). Cannulation with a 31F and 27F Avalon cannula (Avalon Elite<sup>®</sup>, MAQUET Holding B.V. & Co. KG, Germany) was unsuccessful in the RIJ, but was achieved using a 20F RIJ return and 24F left femoral drainage single lumen cannulas.



**Figure 1.** Chest X Ray of patient 1 in the previous 24 hrs prior to ECMO initiation



**Figure 2.** Chest X Ray of patient 2 in the previous 24 hrs prior to ECMO initiation



**Figure 3.** Chest X Ray of patient 3 in the previous 24 hrs prior to ECMO initiation

During the first 48 hours, oxygen saturations remained about 85% while the patient developed IAH progressing towards ACS with pressures up to 38 mm Hg. Supportive therapy included antimicrobials, total parenteral nutrition and CVVH. IAH had resolved by day 5. A tracheostomy was performed on day 8 and he was weaned off ECMO after 219 hours.

**PATIENT 3**

A 46-year-old male, weighing 100kg, with a history of alcohol intake exceeding 140 units per week presented with acute pancreatitis. Initially, he was managed on a surgical ward. Within 48 hours he developed respiratory failure and required intubation and ventilation. CT imaging confirmed pancreatitis with discernible necrosis. Oxygen requirements increased and there were two episodes of prone positioning with short term improvements. After four days of heavy ventilation, he was referred for ECMO. Cannulation of the right internal jugular vein with a 31F Avalon cannula (Avalon Elite®, MAQUET Holding B.V. & Co. KG, Germany) achieved flows of 5 litres.

The first 72 hours of care included achieving a negative fluid balance with CVVH and antimicrobial treatment of Staphylococcus aureus isolated from a tracheal aspirate with Piperacillin/tazobactam and Clindamycin.

The white cell count and C-reactive protein, CRP peaked at  $16.7 \times 10^9/l$  and 501 mg/l respectively. A blood Herpes Simplex Virus PCR was positive and Acyclovir was added. On the initial surgical review, he was absorbing the nasogastric feed hence a conservative management plan chosen.

By day 4 he developed nasogastric feed failure despite prokinetics. A repeat surgical review was requested at the time of recording a maximum IAP of 26 mm Hg (see Table 2).

A large bore NG tube was inserted and allowed free drainage of abdominal contents. Enemas were prescribed with good effect.

On day 7, with falling inflammatory markers, methylprednisolone  $2 \text{ mg kg}^{-1}$  over 24 h in a continuous infusion was started. Repeat bronchoscopies showed evidence of thick tenacious secretions. As the patient developed an Escherichia coli infection from the bronchial lavages, Meropenem was added.

By day 8, IAP was down to 12 mm Hg. A repeat CT scan showed resolution of the pancreatitis. By day 11, lung compliance remained poor and he was placed in the prone position for 16 hours. On day 15, the patient was successfully trialled off ECMO and later discharged to the general Intensive Care Unit. He has since had a percutaneous pancreatic necrosectomy and has been discharged home.

**DISCUSSION**

We present the successful treatment of severe acute pancreatitis in three patients requiring VV-ECMO. To our

**Table 2.** Pre-, during and post-ECMO data in 3 patients

Patient	Pre ECMO			During ECMO			Post ECMO		
	Pat 1	Pat 2	Pat 3	Pat 1	Pat 2	Pat 3	Pat 1	Pat 2	Pat 3
Creatinine ( $\mu\text{mol L}^{-1}$ )	81	102	130	256	310	160	65	69	72
Bilirubin ( $\mu\text{mol L}^{-1}$ )	29	54	38	46	63	48	19	31	28
Platelets ( $\times 10^9 \text{ L}^{-1}$ )	198	207	473	53	59	126	169	160	159
SOFA Score	20	16	14	21	19	16	18	15	15
Maximum IAP (mm Hg)	Not recorded	Not recorded	Not recorded	37	38	26	12	8	10
Lung compliance ( $\text{mL cmH}_2\text{O}$ )	24	10	23	< 24	< 10	< 23	30	28	41

Mean  $\text{PaO}_2/\text{FiO}_2$  56 mm Hg, mean Murray Score 3.5, mean duration on ECMO 408 hours. All patients had evidence of Intra-abdominal compartment syndrome (managed with non-surgical strategies), enteral feed and renal failure. Patient 1 had percutaneous ultrasound-guided ascitic drains sited

knowledge this is the first time that the regular monitoring of IAP in this cohort of patients has been reported. The measurement of IAH helped in the decision making process, in particular, when considering abdominal surgical intervention. All the patients survived discharge from hospital and are still alive.

The incidence of pulmonary complications following SAP is approximately 30%. Such patients have a mortality rate of more than 50% in the first week of admission to intensive care, if they require invasive ventilation [9]. Shields *et al.* [10] reviewed comprehensively the mechanisms leading to acute lung injury in SAP. Of interest is that these authors do not mention VV-ECMO as a strategy to rescue patients who fail conventional methods of ventilation.

This is not the first time that the use of VV-ECMO in SAP has been reported in the literature [5, 6]. In 1998, Peek *et al.* described a series of three patients with SAP requiring VV-ECMO. Survival was 100%. None of the patients underwent laparotomy for either exploration or more aggressive intervention. Fourteen years later Bryner and colleagues reported a series of eight patients with similar presentation. Survival in this series was 63%. Five of the eight patients underwent exploratory laparotomy while on ECMO, some of them on more than one occasion. In our series, none of the patients underwent laparotomy while on VV-ECMO.

In a review of the Extracorporeal Life Support Organization (ELSO) registry data [11] gastrointestinal bleeding was identified as a common complication with an incidence of between 3 and 6%. Intestinal ischaemia does not feature as a complication.

Performing a laparotomy while on VV-ECMO is riddled with potential complications and its incidence has not been reported in the literature. Schreiber *et al.* [12] describe a retrospective review from a single centre. Forty-two patients

underwent a laparotomy in the ICU as they were deemed too unstable to be transferred to the operating room. Two of these patients were on ECMO (not clear from the article if this was VA or VV-ECMO). Intestinal ischaemia was suspected in 24% of the patients. Total 28-day mortality was 75.6%.

All the patients in our series had high IAP. Indeed, these patients had many of the risk factors for developing IAH. ACS complicating VA-ECMO has been described in the paediatric literature [13] while all seven cases undergoing decompressive laparotomy died in a subsequent case series [14]. Two separate case reports [15, 16] describe the development of ACS in three adult patients while on VA-ECMO. Mortality was 50 and 100% respectively.

There is a paucity of information with regards to the prevalence and incidence of IAH and ACS in patients undergoing VV-ECMO. Given our 100% survival, we can only but recommend the regular measurement of IAP in these patients. The lack of aggressive surgical intervention did not affect outcomes in our series.

## CONCLUSIONS

Monitoring intra-abdominal pressure is a valuable adjunct to decision making while caring for critically ill patients with acute respiratory distress syndrome related to severe acute pancreatitis that are treated with VV-ECMO.

## ACKNOWLEDGEMENTS

1. The authors declare no financial disclosure.
2. The authors declare no conflict of interest.

## References:

1. Baron TH, Morgan DE: Acute necrotizing pancreatitis. *N Engl J Med* 1999; 340: 1412–1417.
2. Wyncoll DL: The management of severe acute necrotising pancreatitis: an evidence-based review of the literature. *Intensive Care Med* 1999; 25: 146–156.

3. *Nathens AB, Curtis JR, Beale RJ et al.*: Management of the critically ill patient with severe acute pancreatitis. *Crit Care Med* 2004; 32: 2524–2536.
4. *Pastor CM, Matthay MA, Frossard JL*: Pancreatitis-associated acute lung injury: new insights. *Chest* 2003; 124: 2341–2351.
5. *Peek G, White S, Scott ADN et al.*: Severe acute respiratory distress syndrome secondary to acute pancreatitis successfully treated with extracorporeal membrane oxygenation in three patients. *Ann Surg* 1998; 227: 572–574.
6. *Bryner BS, Smith C, Cooley E, Bartlett RH, Mychaliska GB*: Extracorporeal life support for pancreatitis-induced acute respiratory distress syndrome. *Ann Surg* 2012; 256: 1073–1077. doi: 10.1097/SLA.0b013e31825d33c1.
7. *Kirkpatrick AW, Roberts DJ, De Waele J et al.*: Intra-abdominal hypertension and the abdominal compartment syndrome: updated consensus definitions and clinical practice guidelines from the World Society of the Abdominal Compartment Syndrome. *Intensive Care Med* 2013; 39: 1190–206. doi: 10.1007/s00134-013-2906-z.
8. *Holodinsky JK, Roberts DJ, Ball CG et al.*: Risk factors for intra-abdominal hypertension and abdominal compartment syndrome among adult intensive care unit patients: a systematic review and meta-analysis. *Crit Care (London, England)* 2013; 17: R249. doi: 10.1186/cc13075.
9. *Jaber S, Chanques G, Sebbane M et al.*: Noninvasive positive pressure ventilation in patients with respiratory failure due to severe acute pancreatitis. *Respiration* 2006; 73: 166–172.
10. *Shields CJ, Winter DC, Redmond HP*: Lung injury in acute pancreatitis: mechanisms, prevention and therapy. *Curr Opin Crit Care* 2002; 8: 158–163.
11. *Brogan TV, Thiagarajan RR, Rycus PT, Bartlett RH, Bratton S*: Extracorporeal membrane oxygenation in adults with severe respiratory failure: a multi-center database. *Intensive Care Med* 2009; 35: 2105–2114. doi: 10.1007/s00134-009-1661-7.
12. *Schreiber J, Nierhaus A, Vettorazzi E et al.*: Rescue bedside laparotomy in the intensive care unit in patients too unstable for transport to the operating room. *Critical Care* 2014; 18: R123. doi: 10.1186/cc13925.
13. *Gonzalez L*: Utilidad de la monitorización de la presión intrabdominal en el niño crítico. *An Pediatr (Barc)* 2012; 77: 254–260. doi: 10.1016/j.anpedi.2012.01.028.
14. *Rollins MD, Deamorim-Filho J, Scaife ER, Hubbard A, Barnhart DC*: Decompressive laparotomy for abdominal compartment syndrome in children on ECMO: Effect on Support and Survival. *J Pediatr Surg* 2013; 48: 1509–1513. doi: 10.1016/j.jpedsurg.2012.10.052.
15. *Augustin P, Lasocki S, Dufour G et al.*: Abdominal compartment syndrome due to extracorporeal membrane oxygenation in adults. *Ann Thorac Surg* 2010; 90: e40–41. doi: 10.1016/j.athoracsur.2010.06.039.
16. *Maj G, Calabro MG, Pieri M, Melisurgo G, Zangrillo A, Pappalardo F*: Abdominal compartment syndrome during extracorporeal membrane oxygenation. *J Cardiothorac Vasc Anaesth* 2012; 26: 890–892. doi: 10.1053/j.jvca.2011.07.031.

**Corresponding author:**

*Ignacio Malagon FRCA, PhD, FFICM  
 Consultant Cardiac Anaesthetist,  
 University Hospital South Manchester  
 Honorary Senior Lecturer, University of Manchester  
 Southmoor Road  
 Manchester, M23 9LT  
 United Kingdom  
 e-mail: Ignacio.Malagon@uhsm.nhs.uk*